



## Fixed Drug Eruptions – A Study in Tertiary Care Hospital

Sarala N\*<sup>1</sup>, Harish S<sup>1</sup>, Bhuvana K<sup>1</sup>, Rajendra O<sup>2</sup>

1. Departments of Pharmacology, Sri Devaraj Urs Medical College, Sri Devaraj Urs Academy of Higher Education and Research, Tamaka, Kolar, Karnataka.

2. 375, I E CRS, 6TH Blk Banashankari III STG, Banashankari 3rd Stage Bangalore Karnataka.

---

### ABSTRACT

To study the clinical spectrum of occurrence of Fixed Drug Eruptions (FDEs) to different classes of drugs in a tertiary care hospital. Study was conducted by department of Pharmacology, Sri Devaraj Urs Medical College, Kolar for a period of two years. The data was collected from both in and out patients attending to the Dermatology. A total of 94 adverse drug reactions were collected of which 18 were diagnosed as FDEs. Among them 10 were males and 8 females aged between 2- 60 years. Thirteen FDEs were due to NSAIDs and 5 due to antimicrobials. In all these patients the lesions manifested over the extremities, and 10 of them also had it over the lips and 2 patients on genital and oral mucosa respectively. Diclofenac has caused most of the FDEs. Hyperpigmentation is the common presenting feature. Dechallenge and therapeutic rechallenge was observed in all the patients.

**Keywords:** Fixed Drug Eruption, Dechallenge, Rechallenge.

---

\*Corresponding Author Email: [n\\_sarala@rediffmail.com](mailto:n_sarala@rediffmail.com)

Received 16 January 2015, Accepted 21 January 2015

## INTRODUCTION

Drug reactions are very frequently encountered by dermatologists in day to day practice. Fixed drug eruption though usually not fatal, can cause enough cosmetic embarrassment if present on the exposed parts and also due to residual hyper pigmentation. Brocq in 1984, coined the term 'fixed eruption' to describe a pattern of skin eruption due to antipyrene.<sup>1</sup> Fixed drug eruption (FDE) is a cutaneous drug reaction characterized by the recurrent appearance of skin lesions at the same site or sites, each time the responsible drug is administered<sup>2</sup>. The eruption usually appear within 30 minutes to 8 hours after drug exposure. The lesions are characterized by sharp margins, round or oval pruritic plaques of erythema and edema. It typically resolves leaving behind discrete, postinflammatory hyperpigmented macules or patches. The diagnostic hallmark is its recurrence at the previously affected sites<sup>3</sup>. More than 100 drugs have been implicated in causing FDE and the list is steadily growing. The commonest drugs being sulfonamides (Cotrimoxazole, sulfasalazine), NSAIDs (aspirin, paracetamol, ibuprofen), tetracyclines (doxycycline, minocycline), barbiturates, benzodiazepines, dapsone, quinine and codeine.<sup>4</sup> Probably one new drug enters market everyday which may have the potential to produce drug reaction in some form, which is not known<sup>5</sup>. With the availability of over the counter drugs in India the chances of such reactions are high.

## MATERIALS AND METHODS

This study was conducted by department of Pharmacology, Sri Devaraj Urs Medical College, Kolar for a period of two years. Institutional ethics committee approval was obtained. The patients who were diagnosed to have manifested with Fixed Drug Eruptions by the dermatologist were included. Patients with other type of drug reactions were excluded. The details of patients manifesting with FDE and drugs causing them were collected from both in and out patients as well as from patients referred from other departments to dermatology during this period. Detailed history was taken from all the patients including the indication for the use of the drug, history of similar reactions in the past after taking the offending drug and outcome. The diagnosis was done by dermatologist based on morphological and clinical features as well with a dechallenge. Data was analyzed for age, gender, site of reaction, drugs implicated and the outcome.

## RESULTS AND DISCUSSION

A total of 94 adverse drug reactions were reported during the study period. Among these, 18 were diagnosed as FDEs by dermatologist based on history, symptoms and clinical findings. Thus 19.1 % of patients manifesting with adverse drug reactions (ADRs) were FDEs. Among

them 10 were males and 8 females, aged between 2-60 years with male: female ratio of 2.5: 2. Thirteen FDEs were due to NSAIDs and 5 due to antimicrobials. Figure.1 shows the number of patients manifesting with FDE to different drugs. At least one extremity was involved in all the patients, in addition to that 10 patients also had lesions over lips, 2 of them on genitals and oral mucous membrane respectively. The most common morphological manifestation observed was hyperpigmentation followed by mucosal erosion and erythematous lesions. The indication for which the offending drugs were consumed was musculoskeletal pain in 9 patients, diarrhoea in 5 and fever in 4 of them. Dechallenge was done and therapeutic rechallenge was observed in all the patients. Fixed drug eruption (FDE) is a distinctive variant of drug-induced dermatoses, with characteristic recurrence at the same site of the skin or mucous membranes, described by Brocq in 1884, in a patient receiving antipyrene therapy.<sup>1</sup>The diagnosis of FDE is primarily based on the patient's history and clinical picture. In some patients an oral challenge may be done but this is avoided by most physicians because oral provocation carries a risk of generalized serious drug reactions. Patch testing has been utilized as an alternative to oral testing, but only positive tests are helpful<sup>6</sup>. The pathogenesis of FDE is not clear. Localised delayed-type hypersensitivity, local enzyme deficiency and reaginic hypersensitivity have all been suggested as part of the pathophysiological process. It has also recently been suggested that Fas and Fas ligand (Fas L) may mediate apoptosis in FDE. Fas is a cell surface receptor that is highly expressed on a variety of cells of lymphoid or nonlymphoid origin. Fas L is a membrane protein, usually restricted to activated T cells and natural killer cells. Binding of Fas L to Fas on Fas-sensitive target cells causes apoptosis<sup>7</sup>. FDE is commonly seen in the age group between 21 – 40 years with female preponderance<sup>8</sup>. In our study it is seen in the age group between 2- 60 years with male preponderance. Common sites of involvement are lips and genitalia but in this study, predominantly extremities were involved in addition, lesions were also observed over the genitalia and lips. Common morphological pattern is erythematous / pigmented macule<sup>9</sup>. But we observed hyperpigmentation and this may be due to repeated manifestation of FDE which produces lesions at the same site and resulted in hyperpigmentation. FDE are most commonly encountered with drugs containing sulfa group (cotrimoxazole) followed by tetracyclines, metronidazole, NSAIDs, antiepileptics and still adding to the list. The offending drug priority in causing FDE changes depending on the prescription pattern of physician, geographical area, availability of the drug in the area and economic status of the population<sup>1</sup>. In the present study, diclofenac is the commonest drug implicated to cause FDEs and this can be attributed to over the counter availability of NSAIDs.

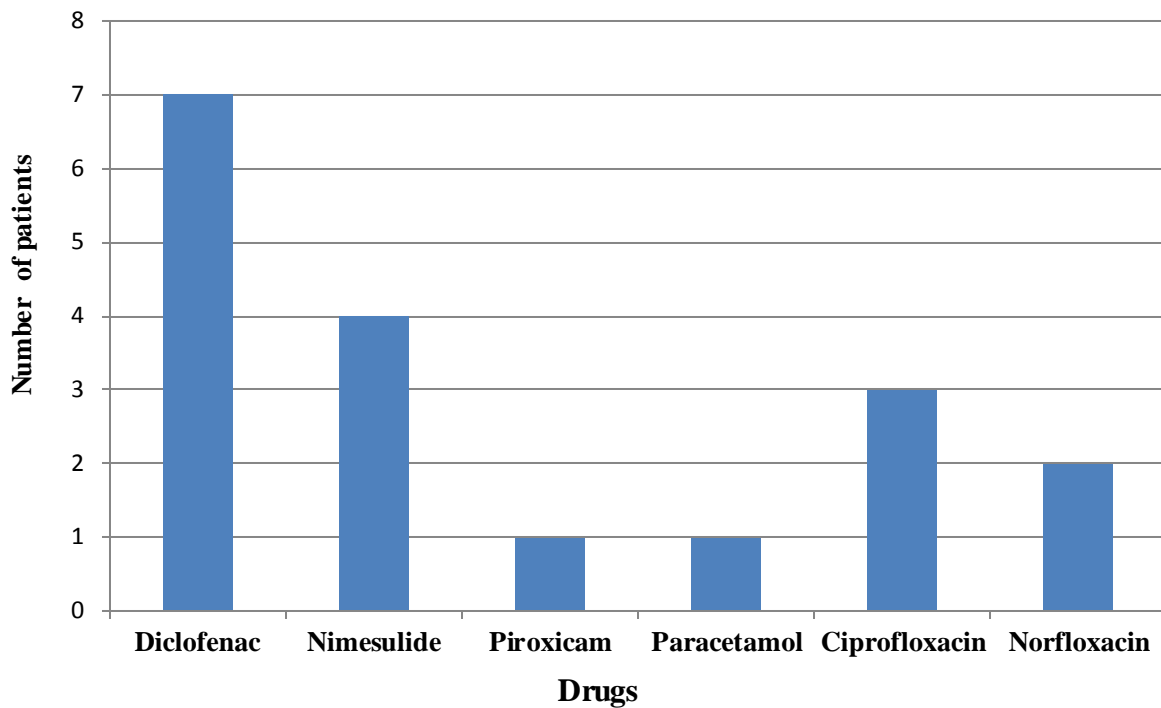


Figure1: Drugs causing FDE

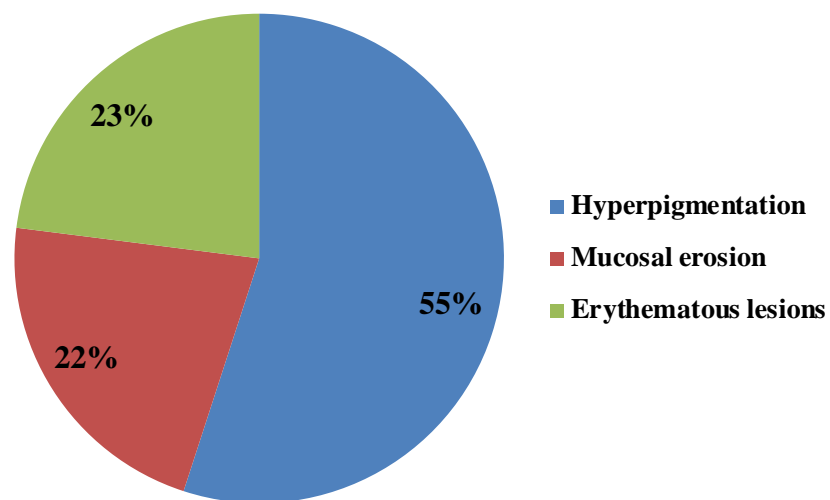


Figure 2 Morphology of lesions

## CONCLUSION

From the present study we can conclude that diclofenac has caused most of the FDEs. Hyperpigmentation is the most common presenting feature. Dechallenge and therapeutic rechallenge was observed in all the patients.

## REFERENCES

1. Gupta R. Drugs causing fixed drug eruptions: confirmed by provocation tests. *Indian J Dermatol Venereol Leprol* 2003; 69: 120 -1.
2. Mohboob A, Haroon TT. Drugs causing fixed eruptions: a study of 450 cases. *Int J Dermatol* 1998; 37: 833-8.
3. Rasi A, Khatami A. Unilateral non-pigmenting fixed drug eruption associated with cotrimoxazole. *Dermatology Online Journal* 2006; 12: 12.
4. Gantsho N, Khumalo NP. Skin Focus: Fixed Drug Eruption. *Current Allergy & Clinical Immunology*. August 2008; 21:138-40.
5. Kanodia SK, Tomar A, Shukla SR. Fixed drug eruption in tertiary care hospital: a study. *J Pharmcovig drugs safety* 2011; 8: 25-8.
6. Braun-Falco O, Plewig G, Wolff HH. Reactions to medications. In: Braun-Falco O, editor. *Dermatology*. 2nd edition. Berlin; Springer: 2000. p 403-430.
7. Choi HJ, Ku JK, Kim MY, et al. Possible role of Fas/Fas ligand-mediated apoptosis in the pathogenesis of fixed drug eruption. *Br J Dermatol* 2006; 154: 419-25.
8. Ozakya – Bayazit E, Bayazit H, Ozaarmagan G. Drugs related clinical pattern in fixed drug eruption. *Eur J Dermatol* 2000; 10: 288-91.
9. Sehgal VN, Srivastava G. Fixed drug eruption (FDE): Changing scenario of incriminating drugs. *International journal of Dermatology* 2006; 45: 897-908.



**AJPHR is**  
**Peer-reviewed**  
**monthly**  
**Rapid publication**  
**Submit your next manuscript at**  
**[editor@ajphr.com](mailto:editor@ajphr.com) / [editor.ajphr@gmail.com](mailto:editor.ajphr@gmail.com)**