



## **The Study of Biochemical Parameters And Histopathological Changes In Liver of Albino Rats To Find out The Effect of Extract of *Sechium edule* Roots Against Paracetamol Induced Hepatic Damages**

**Bapi Ray Sarkar<sup>1\*</sup>, Biplab Kumar Dey<sup>1</sup>, Mr. Kamal Sharma<sup>1</sup>**

*1. Institute of Pharmacy, Assam down town University, Panikhaiti, Guwahati, Assam, India, Pin-781026*

### **ABSTRACT**

The present study was conducted to evaluate the hepatoprotective activity of Ethanolic extract of *Sechium edule* against paracetamol induced liver damage in rats. The Ethanolic extract of *Sechium edule* (300mg/kg & 600mg/kg) was administered orally to the animals with hepatotoxicity induced by single dose of Paracetamol (2gm/kg). Silymarin (25mg/kg) was given as reference standard. All the test drugs were administered orally by suspending in 0.5% Carboxy methyl cellulose (CMC) solution. The Ethanolic extract of leaves of plant *Sechium edule* in the doses of 300mg/kg, 600mg/kg body wt, reduced the levels of serum SGPT, SGOT, ALP and Total bilirubin and increased the Total protein level significantly. In the histopathological studies of the liver section of rats showed the significant recovery with the Ethanolic extract of *Sechium edule* when compared with Control group and Paracetamol treated group.

**Keywords:** *Sechium edule*, Paracetamol, Hepatoprotective, Bilirubin.

\*Corresponding Author Email: mailmebrs@gmail.com

Received 18 March 2016, Accepted 28 March 2016

## INTRODUCTION

The liver plays a central role in transforming and clearing chemicals and is susceptible to the toxicity from these agents. Hepatotoxicity implies chemical-driven liver damage. Certain medicinal agents when taken in overdoses and sometimes even when introduced within therapeutic ranges may injure the organ. Other chemical agents such as those used in laboratories and industries, natural chemicals (e.g. microcystins) and herbal remedies can also induce hepatotoxicity. Chemicals that cause liver injury are called hepatotoxins. More than 900 drugs have been implicated in causing liver injury and it is the most common reason for a drug to be withdrawn from the market. Chemicals often cause subclinical injury to liver which manifests only as abnormal liver enzyme tests. Drug induced liver injury is responsible for 5% of all hospital admissions and 50% of all acute liver failures.<sup>1</sup>

Liver disease is still a worldwide health problem. Unfortunately, conventional or synthetic drugs used in the treatment of liver diseases are inadequate and sometimes can have serious side effects<sup>2</sup>. In the absence of a reliable liver protective drug in modern medicine there are a number of medicinal preparations in Ayurveda recommended for the treatment of liver disorders. In view of severe undesirable side effects of synthetic agents, there is growing focus to follow systematic research methodology and to evaluate scientific basis for the traditional herbal medicines that are claimed to possess hepatoprotective activity.<sup>3</sup> Traditionally it is reported that the plant *Sechium edule* from Cucurbitaceae family used for the treatment of dysentery, various vaginal problems and inflammations, burning sensation, fatigue, various liver disorder, Jaundice etc. So in the present study of the plant belongs to Cucurbitaceae family has been investigated for hepatoprotective activity against Paracetamol induced hepatotoxicity in rats.<sup>4</sup>

## MATERIALS AND METHOD

### **Plant Materials:**

The entire plant *Sechium edule* was collected from Jalpaiguri district of West Bengal, India during the month of June-July. They were thoroughly washed in running water, segregated from the grass and other extraneous material and the field data of the plant like its height, flower color and soil condition were noted in the note book. The authentication was carried out by the help of Department of Botany, University of Calcutta, Kolkata, W.B., India. Then the roots were taken and dried in shade for 30 days. The shade-dried roots were powdered about 1kg and were extracted with ethanol in a Soxhlet apparatus. Extract was evaporated and taken for the pharmacological studies.<sup>5,6</sup>

**Drugs and Chemicals:**

Silymarin was purchased from Micro labs, Tamilnadu, India. SGOT, SGPT, ALP, Bilirubin and Total Protein kits were procured from Span Diagnostics, Surat, India & Transasia Bio-Medicals Ltd. Paracetamol (Pure) was purchased from AGAPE Pharmaceuticals, Sikkim, India. All other chemicals were obtained from local sources and were of analytical grade.

**Animals:**

Albino rats (Wistar strain) weighing 100 gm-120 gm of either sex were used for the study. The animals was procured and housed in the animal house of Institute of Pharmacy, Assam down town University, Guwahati, Assam, India at least 2 weeks prior to the study, So that animal could adapt to the new environment. Animal house was well maintained under the standard hygienic conditions, at a temperature ( $22 \pm 2^{\circ}\text{C}$ ), room humidity ( $60 \pm 10\%$ ) with 12 hrs day and night cycle, with food and water. Total 30 Rats were housed in 5 groups of 6 per cage. Cleaning and sanitation was done on alternate days. Paddy husk was provided as bedding material which was cleaned every day. The cages were maintained clean. All the pharmacological work was carried out after obtaining the approval from the Institutional Animal Ethical Committee.

**Working Protocol**

**Group I:** Control group (Vehicle)

**Group II:** Normal saline (5ml/kg) for 6 days + single dose of Paracetamol (2gm/kg) orally on day 7<sup>th</sup>.

**Group III:** Standard group treated with Silymain 25 mg/kg orally for 6 days + single dose of Paracetamol (2gm/kg) orally on day 7<sup>th</sup>.

**Group IV:** Test group treated with ethanolic extract (300 mg/kg) + single dose of Paracetamol (2gm/kg) orally on day 7<sup>th</sup>.

**Group V:** Test groups treated with ethanolic extract (600 mg/kg body weight) orally for 6 days + single dose of Paracetamol (2gm/kg) orally on day 7<sup>th</sup>.

**Experimental Details**

Animals were randomized and divided into five groups (I-V) of six animals in each group.

**Group I** served as untreated control and fed orally with 0.5% CMC of 5ml/kg body weight daily for seven days. **Group II** rats were treated orally with the standard drug Silymain (25 mg/kg) orally for 6 days and single dose of Paracetamol (2gm/kg) orally on 7<sup>th</sup> day. **Group III** rats were treated with Normal saline (5ml/kg) orally for 6 days and single dose of Paracetamol (2gm/kg) orally on day 7<sup>th</sup>. **Group IV** (Test group) rats were treated with Ethanolic extract (300 mg/kg) for 6 days and single dose of Paracetamol (2gm/kg) orally on day 7<sup>th</sup>. Similarly, **Group V**(test

group) rats were treated with Ethanolic extract (600 mg/kg body weight) orally for 6 days and single dose of Paracetamol (2gm/kg) orally on day 7<sup>th</sup>. For the proper dissolving of Silymarin, Paracetamol and Ethanolic extracts with purified water respectively the 0.5% CMC (Carboxy methyl cellulose) were used. Hepatotoxicity was induced by oral administration of a single dose of paracetamol (2 gm/kg body weight). After 48 hours of treatment, blood was collected by intracardiac puncturing and was allowed to coagulate at room temperature for 30 minutes. Serum was separated by centrifugation at 3000 rpm for about 5 minutes. The clear straw colored serum was collected and stored at (2-8)°C for the measurement of marker enzymes levels to assess the liver functions.<sup>7,8,9</sup>

#### Assessment of biochemical parameters

Estimation of **SGOT, SGPT and ALP** were done with the reagents supplied in the kits (Span Diagnostic Ltd.) which were reconstituted, mixed with serum as directed. The SGOT and SGPT were measured at 340nm and expressed as IU/L. The serum alkaline phosphatase (ALP) was estimated by mixing with the reagent (*p*-nitro phenyl phosphate, magnesium, buffers and stabilizers) with serum, estimated at 405 nm and expressed as IU/L. **Total Protein** concentration was measured by using standard method of Lowery. The total protein was estimated at 555 nm and expressed as mg/dl. **Total Bilirubin** was estimated by Diazo method of Pearlman and Lee with the help of reagents in the kits (Transasia Bio-Medicals Ltd.) measured at 546 nm and expressed as mg/dl.<sup>10,11</sup>

**AST was estimated by Modified UV (IFCC), Kinetic assay method<sup>11, 12</sup>**

**Table 1. Procedure**

Pipette into tube marked	Test
Serum/Plasma	100µL
Working AST reagent	1000µL

- Mix well and aspirate immediately for measurement.
- Programme the analyser as per assay parameters.
- Blank the analyzer with purified water.
- Read absorbance after 60 seconds. Repeat reading after every 30 seconds i. e. upto 120 seconds at 340 nm wavelength.
- Determine the mean absorbance change per minute ( $\Delta A/\text{minute}$ ).

**ALT was estimated by Modified UV (IFCC), Kinetic assay method<sup>12, 13</sup>**

**Table 2. Procedure**

Pipette into tube marked	Test
--------------------------	------

Serum/Plasma	100 $\mu$ L
Working ALT reagent	1000 $\mu$ L

- Mix well and aspirate immediately for measurement.
- Programmed the analyzer as per assay parameters.
- Blank the analyzer with purified water.
- Read absorbance after 60 seconds. Repeat reading after every 30 seconds i. e. upto 120 seconds at 340 nm wavelength.
- Determine the mean absorbance change per minute ( $\Delta A/\text{minute}$ ).

ALP was estimated by *p*NPP-AMP (IFCC), Kinetic assay method<sup>12, 13</sup>

**Table 3. Procedure**

Pipette into tube marked	Test
Serum/Plasma	20 $\mu$ L
Working ALP reagent	1000 $\mu$ L

- Mix well and aspirate immediately for measurement.
- Programmed the analyzer as per assay parameters.
- Blank the analyzer with purified water.
- Read absorbance after 30 seconds. Repeat reading after every 30 seconds i. e. upto 120 seconds at 405 nm wavelength.
- Determine the mean absorbance change per minute ( $\Delta A/\text{minute}$ ).

**Total protein estimation done by standard method of Lowery<sup>14</sup>**

Protein concentration was measured by using standard method of Lowery.

#### **Preparation of Lowry solution**

It was prepared by mixing the following solutions i.e. Solution A, Solution B and Solution C in a ratio of 100: 1: 1 respectively.

Solution A: 2.8598g NaOH was dissolved in 200 ml distilled water then in it 14.3084g Na<sub>2</sub>CO<sub>3</sub> was added, the volume was made up to 500 ml with distilled water.

Solution B: 1.4232g of CuSO<sub>4</sub>.5H<sub>2</sub>O was dissolved in 80 ml distilled water and the volume was made up to 100 ml with distilled water.

Solution C: Dissolve 2.85299g Na<sub>2</sub>-tartarate,2H<sub>2</sub>O was dissolved in 80 ml distilled water and the volume was made up to 100 ml with distilled water.

#### **Preparation of Folin reagent**

5 ml of 2N Folin Ciocalteu's Phenol reagent was mixed with 6 ml of distilled water. This solution is light sensitive so it was prepared at the last 5 minutes of the first sample incubation and was kept in an amber colour container.

## Procedure

The sample was taken out from freezer to thaw. The samples were vortexed well and 0.5 ml was transferred in 10 ml glass tube. Then in it 0.7 ml Lowry solution was added and capped well. The tubes were vortexed briefly for mixing. It was then incubated for 20 min at room temperature in dark. After 20 min of incubation the samples were taken out and 0.1 ml Folin reagent were added to each tube. The tubes were capped and vortexed for mixing. The tubes were incubated once more for 30 min. After 30 min the samples were vortexed again. The samples were transferred in a cuvette and measure the absorbance against blank. From the standard curve of BSA (Bovine serum albumin), the protein concentration were calculated.

## Histopathological examination<sup>15,16</sup>

The blood was collected by intracardiac puncture and the liver was removed, sliced and washed in saline. Liver pieces were preserved in 10% formalin (10% formaldehyde diluted using normal saline) for histopathological study. The pieces of liver were processed and embedded in paraffin wax. Sections were made about 4-6  $\mu$ m in thickness, stained with haematoxylin and eosin. They were mounted and observed under light microscope for histological changes.

## Statistical analysis

The data are expressed as Mean  $\pm$  SEM. Where, N=6(rats). Statistical analysis was made by one way ANOVA followed by Dunnett multiple comparison test; p values <0.01 are considered as significant when compared with Control group (**Group I**) and p values <0.01 are also considered as significant when compared with Paracetamol treated group (**Group II**). Highest significant difference test has been performed with Graph pad instat software.

## RESULTS AND DISCUSSION

**Table 4. Biochemical Parameters of Liver**

Treatment mg/kg.p.o	SGPT /ALT(IU/L)	SGOT / AST(IU/L)	ALP (IU/L)	Total Bilirubin(mg/dl)	Total Protein(mg/dl)
Vehicle Control	40.45 $\pm$ 0.45	68.55 $\pm$ 0.70	52.13 $\pm$ 0.52	0.805 $\pm$ 0.002	7.550 $\pm$ 0.415
Paracetamol (2gm/kg)	220.65 $\pm$ 0.90 <sup>a</sup>	271.13 $\pm$ 1.1 <sup>a</sup>	231.71 $\pm$ 0.92 <sup>a</sup>	2.577 $\pm$ 0.168 <sup>a</sup>	3.451 $\pm$ 0.089 <sup>a</sup>
Silymarin 25mg/kg + Paracetamol	61.18 $\pm$ 0.45 <sup>a,b</sup>	81.25 $\pm$ 0.58 <sup>a,b</sup>	70.94 $\pm$ 0.31 <sup>a,b</sup>	0.977 $\pm$ 0.003 <sup>a,b</sup>	5.950 $\pm$ 0.061 <sup>a,b</sup>
EtOH ext 300mg/kg + Paracetamol	145.69 $\pm$ 0.58 <sup>a, b</sup>	179.91 $\pm$ 0.70 <sup>a, b</sup>	169.41 $\pm$ 0.52 <sup>a, b</sup>	1.799 $\pm$ 0.030 <sup>a,b</sup>	3.905 $\pm$ 0.138 <sup>a,b</sup>
EtOH ext 600mg/kg + Paracetamol	76.05 $\pm$ 0.32 <sup>a,b</sup>	96.05 $\pm$ 0.45 <sup>a,b</sup>	85.63 $\pm$ 0.68 <sup>a,b</sup>	1.510 $\pm$ 0.139 <sup>a,b</sup>	5.803 $\pm$ 0.091 <sup>a,b</sup>

Where, EtOH = Ethanolic Extract of *Sechium edule*

All Values are expressed as Mean  $\pm$  SEM. n = 6 rats in each group. <sup>a</sup>, P<0.01 compared to control group; <sup>b</sup>, P<0.01 compared to Paracetamol-treated group.

### Graphical representation of Biochemical Parameters

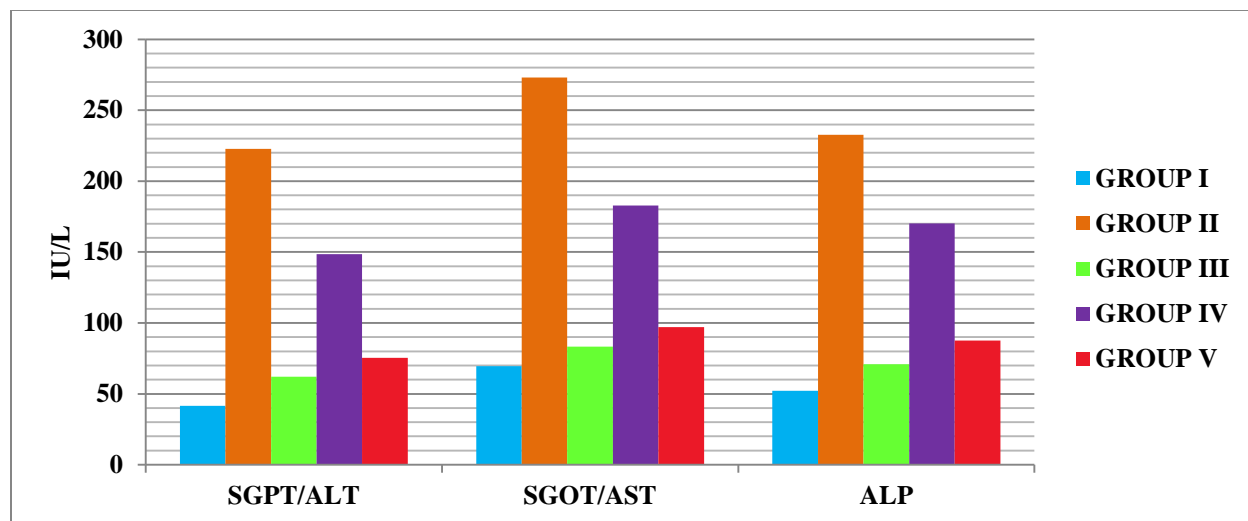


Figure 1. Graphical representation of SGPT, SGOT, ALP level of all groups (Group I=Control (Vehicle) group, Group II=Paracetamol-induced group, Group III= Silymarin treated group, Group IV= Ethanolic extract, 300mg/kg, Group V= Ethanolic extract, 600mg/kg) in Paracetamol induced Hepatotoxicity

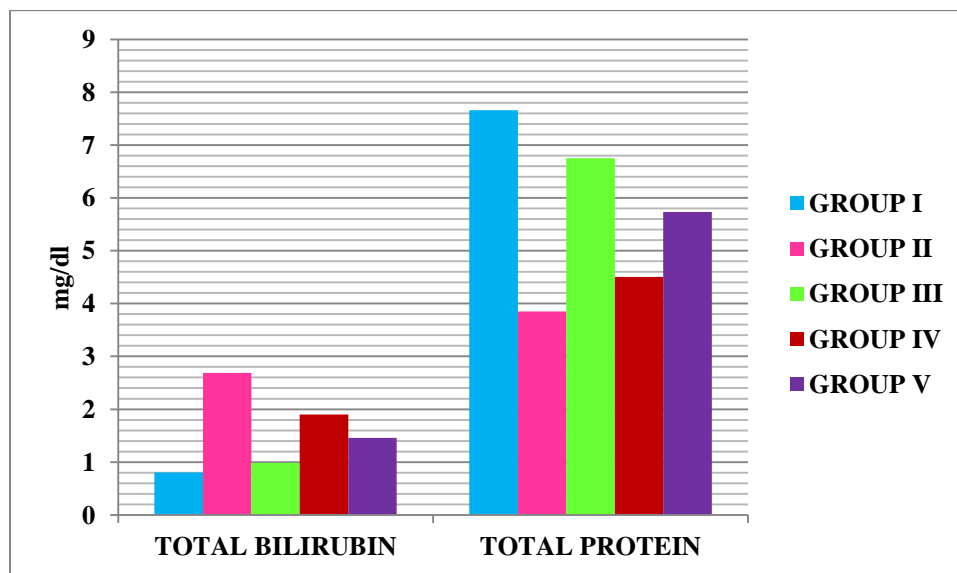
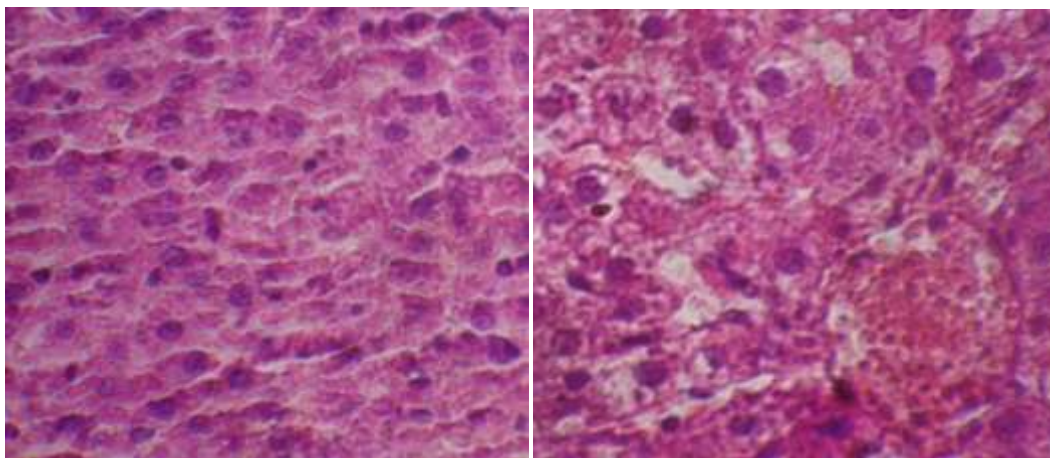
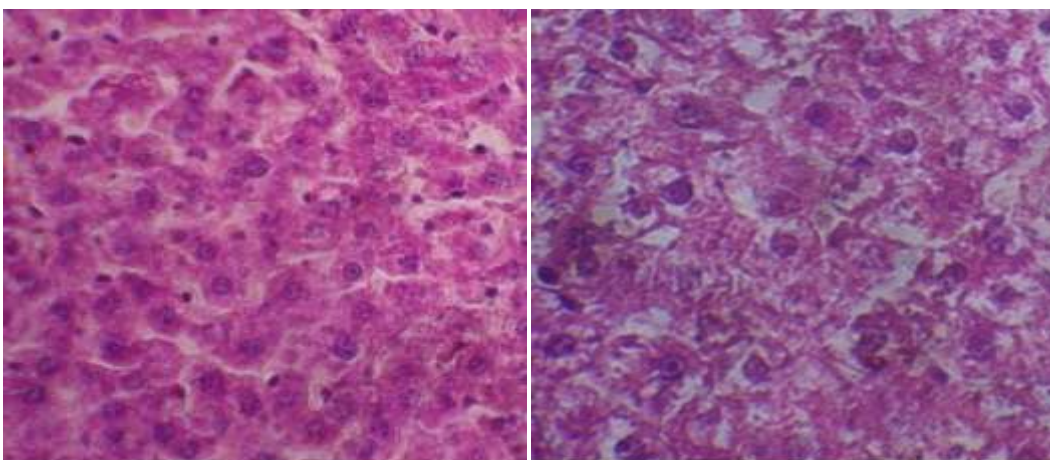


Figure 2. Graphical representation of Total Bilirubin and Total Protein level of all groups (Group I=Control (Vehicle) group, Group II=Paracetamol-induced group, Group III= Silymarin treated group, Group IV= Ethanolic extract, 300mg/kg, Group V= Ethanolic extract, 600mg/kg) in Paracetamol induced Hepatotoxicity.

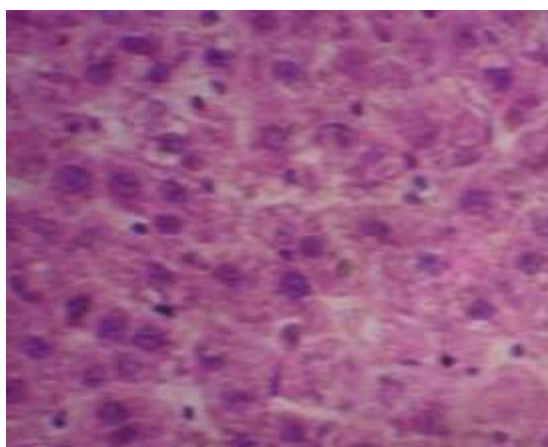
**Histopathological changes in Liver**

**Figure 3. Treated with CMC (Control group)    Figure 4. Treated with Paracetamol**



**Figure 5. Treated with Silymarin**

**Figure 6. Treated with EtOH ext. (300mg/kg)**



**Figure 7. Treated with EtOH ext. (600mg/kg)**

**DISCUSSION**

Treatment with Paracetamol by administering 2gm per kg of body weight at a single dose in albino rats caused considerable increase of SGOT (also known as aspartate transaminase, AST),

SGPT (also known alanine transaminase, ALT), ALP (Alkaline phosphatase), Total bilirubin and decrease of Total protein. Estimation of the serum level revealed that paracetamol induced a remarkable increase of SGPT, SGOT, ALP, Total bilirubin and decrease the Total protein level by comparison to the control animals. Ethanolic extract at dose 300mg/kg body weight reduced these paracetamol induced level of SGOT, SGPT, ALP & Total bilirubin by 33.26%, 33.11%, 26.86% and 29.72% respectively and increase the Total protein by 12.82% where as the dose at 600mg/kg body weight reduced these paracetamol induced level of SGPT, SGOT, ALP & Total Bilirubin by 66.16%, 64.46%, 32.39% and 48.11% respectively and increase the Total protein by 21.54%. The results were found to be statistically significant and the '*p*' values were less than 0.01%. These observations inferred Ethanolic extracts might contain hepatoprotective principles and the higher dose (600mg/kg body weight) of the extract shows more significant result than the dose 300mg/kg body weight. Paracetamol at higher doses causes hepatic necrosis due to increased formation of reactive intermediate such as *N*-acetyl-*p*-benzo-quinone imine (NAPQI) by oxidation through the cytochrome P-450 mixed function oxidase system and NAPQI is then irreversibly conjugated with the SH groups of glutathione. Attenuation of the necrotic effect of paracetamol by the extract might be due the reversible inhibition of the oxidative enzymes.

Histo-pathological study of liver sections of control group showed normal cellular architecture with distinct hepatic cells, sinusoidal spaces and central vein (Figure 3.). In the liver sections of paracetamol intoxicated rats (Figure 4.), there was disarrangement and degeneration of normal hepatic cells with intense centrilobular necrosis, sinusoidal hemorrhages, fatty changes, cytoplasmic vacuolization and inflammatory changes. Treatment with Standard drug silymarin showed the prominent protection of liver (Figure 5.). Treatment with the ethanolic extract (300mg/kg) showed less amount protection (Figure 6.), but the ethanolic extract (600mg/kg) exhibited prominent protection against paracetamol intoxication, which was evidenced by less centrilobular necrosis, less vacuole formation, reduced sinusoidal dilation, and less disarrangement and degeneration of hepatocytes (Figure 7.). These studies suggest that the ethanolic extract of *Sechium edule* protected the hepatic necrosis by inhibiting enzymatic oxidation.

## CONCLUSION

The Ethanolic extracts of roots of plant *Sechium edule* found to have significant hepatoprotective activity against Paracetamol induced hepatotoxicity in Wistar rats. The effect is almost comparable to silymarin or slightly less. Ethanolic extract of roots of plant *Sechium edule* in the

doses of 300mg/kg and 600mg/kg body wt, reduced the levels of serum SGPT, SGOT, ALP and Total bilirubin and increased the Total protein level. These observations inferred that Ethanolic extract at higher dose (600mg/kg body wt) shows more significant result than the dose 300mg/kg body wt. In the histopathological studies of the liver section of rats showed the significant recovery with the roots of Ethanolic extracts of *Sechium edule* against Paracetamol induced hepatotoxicity. The research outcome is to establish the hepatoprotective activity of the plant to rationalize its use as a drug to give more emphasis on this plant for the development of medicinal value.

## REFERENCES

1. Friedman, Scott E, Grendell, James H, McQuaid, Kenneth R, Current diagnosis & treatment in gastroenterology, Lang Medical Books/McGraw-Hill., New York, 2003; 664–679.
2. Guntupalli M, Hepatoprotective effects of rubiadin, a major constituent of *Rubia cordifolia* Linn. *J. Ethnopharmacol.* 2006; 103, 484–490.
3. Chatterjee T K, Medicinal plants with hepatoprotective properties. In: Herbal Options. 3rd Edn. Books and Allied (P) Ltd. Calcutta. 2000; 135.
4. Gurung B, “The medicinal plants of the Sikkim Himalaya” 1<sup>st</sup> ed, Jasmin Bejoy Gurung, West Sikkim, 2002; 292-3.
5. Harborne J B, Phytochemical methods. A Guide To modern Technique of Plant Analysis, 3<sup>rd</sup> edn, London, 1998; 2, 5-7, 55-82.
6. Kokate C K, Practical Pharmacognosy, 4th reprint (ed), New Delhi, Vallabh Prakashan., 2005; 122-125.
7. Gupta A K’ Hepatoprotective activity of *Rauwolfia serpentina* rhizome in paracetamol intoxicated rats. *J. Pharmacol. Toxicol.* 2006; (1) ,82-88.
8. Vogel G H, Vogel W H, Drug discovery and evaluation, Pharmacological assays, Springer, Berlin, 2002; 847,878,879.
9. Gosh M N, Fundamentals of Experimental Pharmacology, 4<sup>th</sup> ed, S K Ghosh Publisher, Kolkata, 2008; 176-79.
10. Moron M S, Depierre J W and Mannervik B. Levels of glutathione, glutathione reductase and glutathione-S-transferase activities in rat lung and liver. *Biochem Biophys Acta.* 1979; 582, 67-78.

11. Kind P R N and King E J, Estimation of plasma phosphatase by determination of hydrolysed phenol with amino antipyrine. *J Clin Pathol.* 1954; 7, 322.
12. Reitman S, Frankel S, In vitro determination of transaminase activity in serum, *Am. J. Clin. Pathol.* 1957; 28, 56.
13. Nkosi C Z, Opoku A R and Terblanche S E, Effect of pumpkinseed (*Cucurbita pepo*) protein isolate on the activity levels of certain plasma enzymes in CCl<sub>4</sub>-induced liver injury in rats. *Phy.the.Res.*2005; 19, 341–345.
14. Lowry O H, Rosebrough N J, Far A L, Randall R J, Protein measurement with Folin Phenol reagent, *J Biol Chem* 1951; 193, 265-275.
15. Baheti J R, Goyal R K, Shah J K, Hepatoprotective activity of *Hemidesmus indicus* R. Br. In rats, *Indian Journal of Experimental Biology*, 2006; (44), 309-402.
16. Manokaran S, Jaswanth A, Sengottuvelu S, Nandhakumar J, Duraisamy R, Karthikeyan D, Mallegaswari R, Hepatoprotective Activity of *Aerva lanata* Linn. Against Paracetamol induced Hepatotoxicity in Rats, *Research J. Pharm. and Tech.*, 2008; 1(4), 398-400.
17. Louis H. Aung, Amelia Ball, Mosbah Kushad, Developmental and nutritional aspects of chayote (*Sechium edule*, Cucurbitaceae), *Economic botany*, April–June 1990, Volume 44, Issue 2; 157-16.
18. George J. Flick Jr., Louis H. Aung, Robert L. Ory, Allen J. St. Angelo, Nutrient composition and selected enzyme activities in *sechium edule*, *Journal of Food Science*, January 1977, Volume 42, Issue 1; 11–13.
19. T.sundarrajan, T.Raj Kumar<sup>1</sup>, E.Udhayakumar<sup>1</sup>, M.Sekar<sup>1</sup> and M.K.Senthil, *International Journal of Pharma and Bio Sciences*, volume 2, Issue 1, Jan-Mar 2011,128.
20. Yang XX, Hu ZP, Duan W, Zhu YZ, Zhou SF. Drug-herb interactions: eliminating toxicity with hard drug design. *Curr Pharm Des.* 2006; 12(35); 4649-64.
21. Dahanukar S.A., Kulkarni R.A., Rege N.N. Pharmacology of medicinal plants and natural products. *Indian J. Pharmacol.* 2000, 81–118.
22. Jeanne Grunert, advantages and disadvantages of herbal medicines, Current Status of Herbal Drugs in India: An Overview, *J Clin Biochem Nutr.* 2007;41(1),1–11.
23. Jain Sk., Director of Indian Folk medicine and Ethno botany, Deep Publications New Delhi, 1992, 75.
24. Sikarwar RIS, Ethno botany of Madhya Pradesh (Review Article), *Appl Bot Abstr*, 2001, 21(2),133-147.

25. Cragg GM, Newman DJ, Snader KM. Natural products in drug discovery and development. J Nat Prod 1997; 60, 52-60.
26. Chopra RN, Noyar SL and Chopra IR, Glossary of Indian Medicinal Plants, Publications and Information and Directorate, CSIR, New Delhi, 1956,56-59.



***AJPHR*** is  
Peer-reviewed  
monthly  
Rapid publication  
Submit your next manuscript at  
[editor@ajphr.com](mailto:editor@ajphr.com) / [editor.ajphr@gmail.com](mailto:editor.ajphr@gmail.com)