



Atypical BPPV –The Diagnosis and Treatment Modalities.

Nilotpal Dutta*, Soumik Basu

ABSTRACT

Dix Hallpike Maneuver is performed to diagnose Benign Paroxysmal Positional Vertigo and is still relevant in the clinical evaluation of BPPV. However in clinical practice we routinely get cases of vertigo due to postural changes or head movements which do not follow the typical sign of Dix Hall pike test. These patients can be classified as being suffering from Atypical BPPV. The Aim was to Evaluate BPPV with negative Dix Hallpike test and the treatment modality for it. Selection criteria for our studies were based on perspective clinical studies done in 64 patients with Atypical BPPV at Dept of ENT Audio-vestibular unit, in a tertiary care Hospital for a period of 1 year. Results and observations showed that 56 patients from the study group were symptomatically relieved when Epleys maneuver was performed on them consecutively for 3 days. It is seen that almost 88 % of the patients suffering from Atypical BPPV showed symptom remission when treated with Canalith Repositioning Maneuver specially the Epleys. Thus Epleys maneuver can be a treatment modality for patients suffering from BPPV without nystagmus. Patients with a typical history of positional vertigo who shows no nystagmus in Dix hallpike which we often diagnose as not a case of BPPV are actually atypical BPPVs which can be successfully treated by Epleys manoeuvre, a cheap and easy and effective way of treatment.

Keywords: BPPV, Nystagmus, Epley's maneuver, Vertigo, Dix and Hallpike manoeuvre

*Corresponding Author Email: drnilotpal9@gmail.com
Received 10 September 2019, Accepted October 2019

Please cite this article as: Dutta N. *et al.*, Atypical BPPV - The Diagnosis and Treatment Modalities.. American Journal of Pharmacy & Health Research 2019.

INTRODUCTION

Benign Paroxysmal Positional Vertigo (BPPV), described in 1921 is very likely the most common cause of vertigo, with a prevalence of 20%-30% in specialized clinics. This diagnosis of BPPV is suggested by a history of brief (less than one minute) episode of vertigo that are provoked by rolling over in bed, lying down, sitting up from a supine position, bending over or looking up. BPPV commonly is worse in the early morning and may be absent for weeks or months at a time before returning. It can happen in an unpredictable and sudden way, but it does not have a progressive pattern. Parnes(10) et al. reported that approximately 58% of the BPPV cases do not have a clearly identified cause. Its primary form corresponds to 50-70% of the cases. On the other hand, the second most common cause is head injury (7%-17%), followed by vestibular neuritis (15%). With an annual incidence of 0.6%, it affects more women than men,(11)and its prevalence is seven times higher in people older than 60 years, with an age peak between 70 and 78 years. Consanguineous relatives have five times more likelihood of developing BPPV. Diagnosis rests on the observation of characteristic eye movements accompanying the symptoms of vertigo when a patient's head is moved into a specific orientation with respect to gravity. Dix and Hallpike (12) provided both the provocative maneuver necessary for the accurate diagnosis of the condition, as well as the first description of all the classic features of the accompanying nystagmus: latency, direction, duration, reversal, and fatigability . BPPV occurs when free particles, suspended in the fluid (endolymph) of a patient's vestibular labyrinth, find their way into one of the semicircular canals (SCC). Normally, the canals are excited only by head *rotation*; when particles more dense than endolymph are present in the lumen, however, canals become gravity sensitive, pathologically responding to changes in head *position* . At least in some cases, the particles (canaliths) are otoconia– calcium carbonate crystals, a normal constituent of the otolith organs in the inner ear(13, 14) . Original theories held that the particles were adherent to the cupula, the structure that spans the lumen of the canal and is deflected during head rotation. More recently, free-floating material has been observed intraoperatively in the posterior SCC. All of the features of typical nystagmus provoked by changes in head position in patients with BPPV may be explained by canalithiasis ,each canal has excitatory connections to extraocular muscles that move the eyes in the same plane , the *direction* of the nystagmus depends on the canal that is being stimulated , and the direction of particle movement. The nystagmus seen when lying down may *reverse* direction when the patient moves to the upright position. The *duration* of nystagmus corresponds with the time

needed for particles to come to rest in a new dependent location. Although fatigability is described as a characteristic of nystagmus associated with BPPV, repeated positioning is not recommended, as the diagnosis may be made without subjecting the patient to additional discomfort. Nystagmus in these cases is considered important to characterize the BPPV until current days. Nonetheless, in the clinical practice, there are cases of vertigo caused by movements such as: laying down, turning from one side to the other in bed, fast head movements horizontally and bending over, without nystagmus in the Dix -Hallpike maneuver.

Upon nystagmus and detecting the semi-circular canal involved, the canalith repositioning maneuver has been proven efficient (especially that of Epley for the posterior semi-circular canal). Nonetheless, in the absence of nystagmus, would it be possible to diagnose and treat BPPV?

Given the aforementioned, added to the scarce publications on BPPV without nystagmus, also called subjective or atypical, this non-systematic review is fully justified and its goal is to characterize the BPPV without nystagmus, as well as the treatment approach in such situation.

MATERIALS AND METHOD

The selection criteria for studies were based on clinical study.

Number of Patients :64

Period of study: July 2016 to July 2017

Centre of study: ENT Dept , Audiovestibular Unit ,in a tertiary care hospital , West Bengal , India.

Inclusion Group:

- 1)BPPV wit atypical Dix Hallpike signs(-ve test).
- 2)Persistent vertigo for < 6 monts.
- 3)Age :30 yrs to 60 yrs of age.

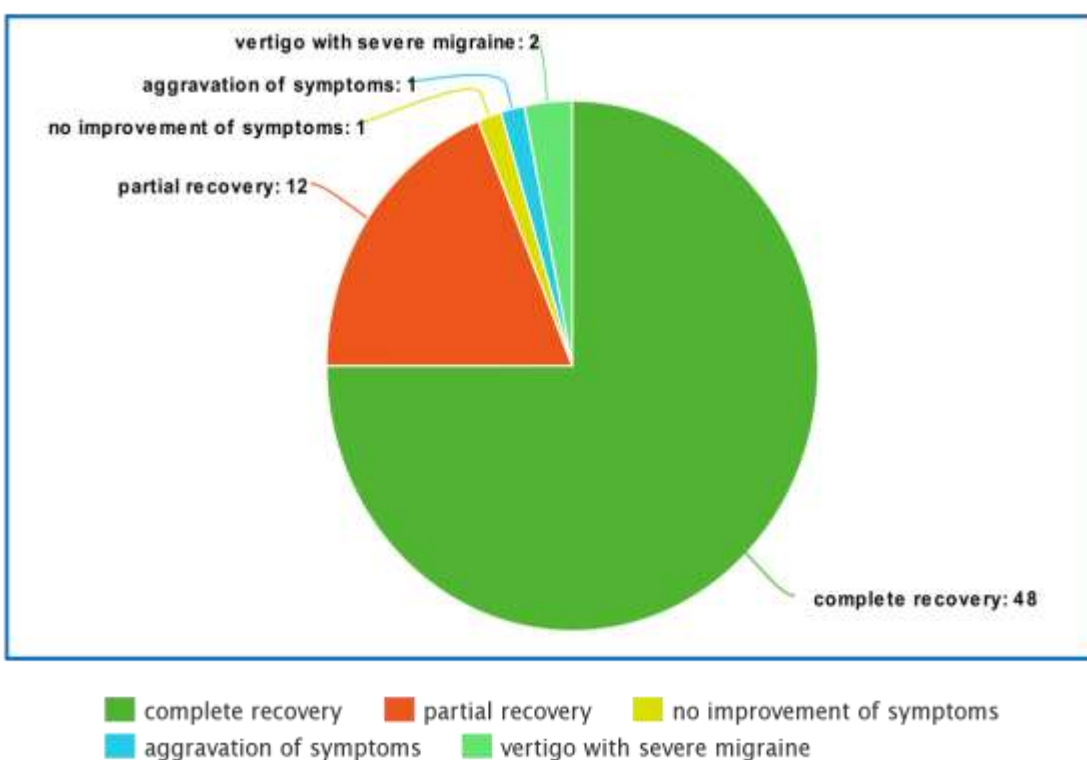
Exclusion group:

- 1)Patient is on anti- vertigo drugs.
- 2)Patients wit typical Dix Hallpike positive results.
- 3)Vertigo for more than 6 months or chronic cases.

The group of 64 patients suffering from BPPV without nystagmus were evaluated by performing the canalith repositional maneuver specially the epleys (for posterior semicircular canal defect)on them for 3 consequitve days, and reassessment was carried out after 5 days.

RESULTS AND DISCUSSION

Study type	Series	Results	Comments
Clinical prospective	In a series of 64 patients with atypical BPPV ,46 patients were having BPPV with vertigo and nausea and 15 presented with vertigo but no symptoms of nausea. 2 in the group presented with vertigo and severe migrane. Only 1 out of the group presented with vertigo coupled with tinnitus and hearing loss.	Studies showed that out of the 64 patients in the group ,48 (75%) showed complete recovery whereas 12 of them had partial recovery .6 % of the patients showed no improvement in their symptoms. But none of them received a worsening in their condition.	The maneuver is both economically and clinically beneficial and convenient to the patient with no life hazards .The treatment failure cases were evaluated further for other causes of vertigo excluding BPPV.



meta-chart.com

The study of BPPV without nystagmus is a perspective study carried out in a tertiary setup. BPPV without nystagmus is characterized by the clinical exam in which the patients complaining of brief BPPV spells without nystagmus and/or nausea associated with changes in head position did not have positional and/ positioning nystagmus. - Three probable explanations could be found for the absence of dizziness and positioning nystagmus in head movement which would enable symptom and ocular phenomenon elimination at that time. The patients could have minimum calcium carbonate particles stuck to the cupule or floating in the affected semicircular

canal, enough to cause nausea and/or vertigo, but not enough to cause nystagmus. Before treating the patient, the maneuver can be negative for BPPV in a first assessment and positive in another one, on the same day or in a different day. Many BPPV cases did not have positioning nystagmus or dizziness at the time of the maneuver, which does not rule out the diagnostic maneuver.

Another explanation for the BPPV without nystagmus was proposed by Johkura, Momoo & Kuroiwa²⁹. They perceived that among elderly citizens with chronic dizziness of unknown cause, without nystagmus in the conventional assessment using Frenzel goggles, diagnosis is very difficult. After investigating 200 elderly with dizziness, in whom they used an infrared camera and video-oculography, they found a faint positional ageotropic horizontal nystagmus, compatible with horizontal semicircular canal (HSCC) BPPV in 98 patients. It is also stressed that the mechanism of this mild nystagmus in the elderly is unknown, and they are also not eligible to make up for the balance disorder caused by this BPPV.

These authors consider that the prevalence of this mild nystagmus is high and its history matches that of BPPV in the elderly, suggesting that the HSCC BPPV is one relatively common cause of chronic dizziness considered of unknown cause in the elderly.

Gans, presented a third explanation based on a change in the calcium metabolism and the consequent non-absorption of free otoliths, which would increase their quantity in the semicircular canals and enable the triggering of vertigo upon head movement.

Dix hallpike was the only method used for diagnosis of BPPV with or without nystagmus and its characteristics.

It was very difficult to recognize the positioning nystagmus type and direction upon simple observation as this ocular phenomenon is mild and short lasted.

However the use of the Frenzel goggles (20 dioptries) or videonystagmography (VNG) which enables the proper identification of the positioning nystagmus, was limited in our setup, which was the other reason behind difficulty in identification of this ocular phenomenon.

The treatment of atypical BPPV was done solely with the canalith repositioning maneuver i.e. the Epley and it was found that almost 94 % of the group showed symptom remission.

Most of the BPPV cases, with or without nystagmus responded favorably to vestibular rehabilitation physical therapy procedures. Ganança stated that vertigo upon head position change enables the identification of the labyrinth involved in the BPPV without nystagmus. But failures can happen because of the movement of crystals to another semicircular canal, creating another BPPV variant.

The papers we found which dealt with atypical BPPV and their findings are listed below

Author	Study type	series	results	comments
Tirelli et al.18/ Laryngoscope/ 2001 (4)	Prospective clinical	43 patients with BPPV without nystagmus. treated by the modified PSCC (posterior semicircular canal) repositioning maneuver reassessment was carried out after 5 days	Complete recovery (60.46%) partial recovery(6.9%) no patient worsened	The maneuver is of low cost and it is not inconvenient to the patient
(7)Haynes, DS et al./ Laryngoscope/ 2002 ¹⁹	Clinical Prospective Comparative	127(78.4%) patients with BPPV and nystagmus and 35(21.6%) with BPPV without nystagmus, detected in the Dix-Hallpike maneuver without the Frenzel goggles, were submitted to the Sémont treatment maneuver, and reassessed 3 weeks late	97(76%) patients with BPPV and nystagmus had complete symptom remission, 19 (15%) patients reported improvement. Among the patients with BPPV without nystagmus, symptom remission happened to 22 (63%) patients and 8 (23%) reported improvements.	The Sémont maneuver proved efficient both in BPPV with or without nystagmus
(5)Koga et al.26 / Rev. CEFAC/2004	Comparative retrospective clinical analysis	167 patients with vertigo and/ or dizziness were assessed by means of vector-electronystag- mography and the Dix Hallpike test with the Frenzel goggles	Of the 167 patients, 68 (40.8%). Complained of dizziness and/ or vertigo associated with a change in head position, which was characterized as BPPV, even in the absence of nystagmus	Patients with BPPV without nystagmus were identified
	Review paper(Ganaca)	. It reinforces the use of Frenzel goggles (of 20 dioptries) or the use of video nystagmography to detect nystagmus	They assessed 17 papers published between 1990 and 2002	They considered BPPV in the presence of vertigo without nystagmus detected in the Dix Hallpike test and stated that nystagmus was present in 50% of the cases
(9) Zhonghua et al.24/Paper	Comparative retrospective clinical analysis	to assess characteristics of BPPV with and without nystagmus	Complete symptom remission was noticed in 11(97.1%) and 79.2 percent with nystagmus by repositioning	BPPV treatment was better in patients without nystagmus

published in Chinese/ 2007/Abstract in English.			maneuvre	
Zhonghua et al. ²⁴ / Paper published in Chinese/ 2007/Abstract in English.	Retrospective Series	They analyzed the charts from 1271 consecutive patients examined in the past 6 years with BPPV by means of the Dix-Hallpike maneuver and the Frenzel goggles	BPPV had prevalence in the age range between 41 and 60 years. 473 (42.2%), females 798 (62.8%), nystagmus and positioning vertigo in 1033 (81.3%). Cure or improvement by means of the particle repositioning maneuver (77.9%); and the possibility of recurrence (21.8%, in one year of follow up). BPPV with vertigo and without positioning nystagmus happened in 238 patients (18.7%).	As far as clinical evolution is concerned, 990 (77.9%) patients became asymptomatic or improved after the first treatment done by means of the repositioning maneuver
	Observational Comparative Cross-sectional(Munaro G &Silveira AF ²³ / Rev. CEFAC/ 2009)	86 patients with clinical history of BPPV who were assessed by means of the positioning tests (Dix-Hallpike and the <i>roll maneuver</i>) and vector-electronystagmography	86 patients with clinical history of BPPV who were assessed by means of the positioning tests (Dix-Hallpike and the <i>roll maneuver</i>) and vector-electronystagmography	BPPV without nystagmus was called atypical

CONCLUSION

Atypical bppv is characterized by vertigo with or without nausea upon head movements but shows no signs of nystagmus upon Dix Hallpike maneuver. The treatment of BPPV without nystagmus was carried out based on the typical history of BPPV and signs found upon physical examination, with vertigo. Treatment was done by Epleys which is a very cheap and easy treatment option, on the side which triggered the symptoms. Full symptom remission among patients with BPPV without nystagmus who were treated was 75% and partial remission was 18% which suggests Epleys as a treatment protocol for BPPV without nystagmus.

Compliance with Ethical Standards

Conflict of interest the authors declare that there is no conflict of interest.

Ethical Approval all procedures performed in studies involving human participants were in accordance with the ethical standards of the institutional and/or national research committee and with the 1964 Helsinki declaration and its later amendments or comparable ethical standards.

Informed consent informed consent was obtained from all individual participants included in the study

REFERENCES

1. Munaro G, Silveira AF. Avaliação vestibular na vertigem posicional paroxística benigna típica e atípica. Rev CEFAC. 2009;11(1):76-84.
2. Anagnostou E, Mandellos D, Patelarou A, Anastasopoulos D. Benign paroxysmal positional vertigo with and without manifest positional nystagmus: an 18-month follow-up study of 70 patients. HNO. 2005;55(3):190-4.
3. Johkura K, Momoo T, Kuroiwa Y. Positional nystagmus in patients with chronic dizziness. J Neurol Neurosurg Psychiatry. 2008;79(12):1324-6.
4. Tirelli G, D'Orlando E, Giacomarra V, Russolo M. Benign positional vertigo without detectable nystagmus. Laryngoscope. 2001;111(6):1053-6.
5. Caldas MA, Ganança CF, Ganança FF, Ganança MM, Caovilla HH. Clinical features of benign paroxysmal positional vertigo. Braz J Otorhinolaryngol. 2009;75(4):502-6.
6. Koga Haynes DS, Resser JR, Labadie RF, Girasole CR, Kovach BT, Scheker LE, et al. Treatment of benign positional vertigo using the Semont maneuver: efficacy in patients presenting without nystagmus. Laryngoscope. 2002;112(5):796-801.
7. Ganança MM, Caovilla HH, Munhoz MSL, Silva MLG, Ganança FF, Ganança CF. Lidando com a Vertigem Posicional Paroxística Benigna. Acta ORL. 2005;23(1):20-

8. Anagnostou E, Mandellos D, Patelarou A, Anastasopoulos D. Benign paroxysmal positional vertigo with and without manifest positional nystagmus: an 18-month follow-up study of 70 patients. *HNO*. 2005;55(3):190-4.
9. L.S. Parnes, S.K. Agrawal and J. Atlas, Diagnosis and management of benign paroxysmal positional vertigo (BPPV), *CMAJ* **169** (2003), 681–693.
10. Schuknecht HF, Ruby RR. Cupulolithiasis. *Adv Otorhinolaryngol*. 1973;20:434-43.
11. Dix R, Hallpike CS. The pathology, symptomatology and diagnosis of certain common disorders of the vestibular system. *Ann Otol Rhinol Laryngol*. 1952;61(4):987-1016.
12. Schuknecht HF, Ruby RR. Cupulolithiasis. *Adv Otorhinolaryngol*. 1973;20:434-43.
13. Hall SF, Ruby RRF, McClure JA. The mechanics of benign paroxysmal vertigo. *J Otolaryngol*. 1979;8(2):151-8



AJPHR is
Peer-reviewed
monthly
Rapid publication
Submit your next manuscript at
editor@ajphr.com / editor.ajphr@gmail.com